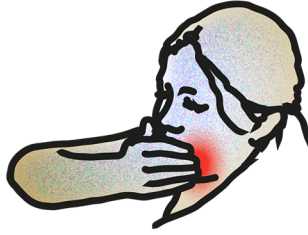

Do any of the following apply?



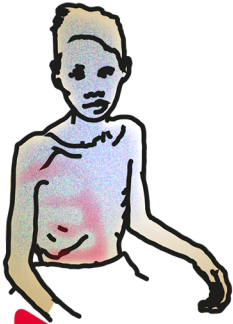nocturnal pain/ drop attacks?



speaking/ swallowing problem?



dizziness?



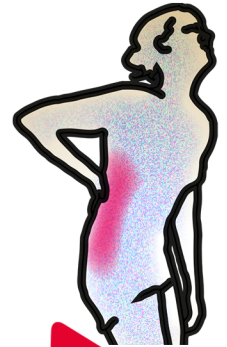weight loss/ fevers?



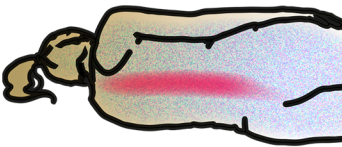
double vision?



severe pain?



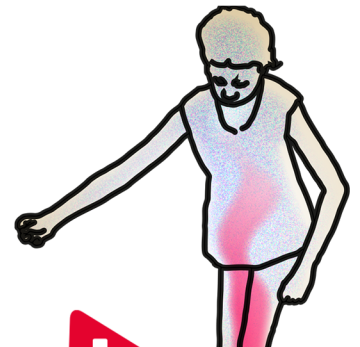
spinal cord compression?



significant vertebral tenderness?



bladder/bowel incontinence?



loss of feeling in both legs?



Does the patient have a pressure relieving cushion?

Seek immediate medical advice if any of the above apply

Are there multiple injuries?

1

AMPUTEE OBJECTIVE ANALYSIS

prioritise and proceed with caution

2

Are there co-morbidities, or previous medical history?

2

proceed with caution, treat as appropriate

3

Does the patient understand and retain new information?

3

monitor, query ability to use prosthesis

4

Is the stump healthy?

4

check for signs of vascular disease or infection

refer to medic

5

Is the stump oedematous?

5

check for signs of oedema by pressing gently with flat of thumb

oedematous stump

6

Has the scar healed?

6

delayed healing

7

Is the scar tethered?

7

tethered scar

8

Is the patient in pain?

8

in pain

9

13

Is the pain in the stump?

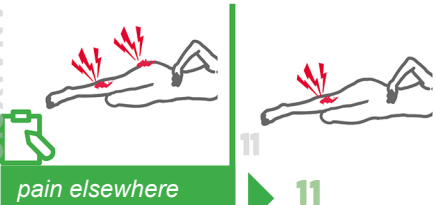
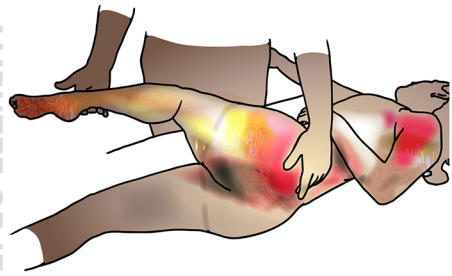
9

pain in the stump

10

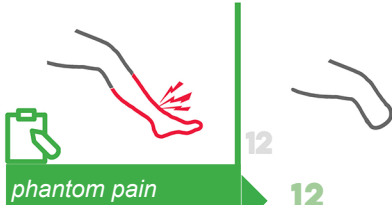

Is the pain elsewhere?

10



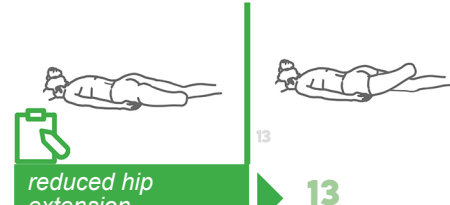
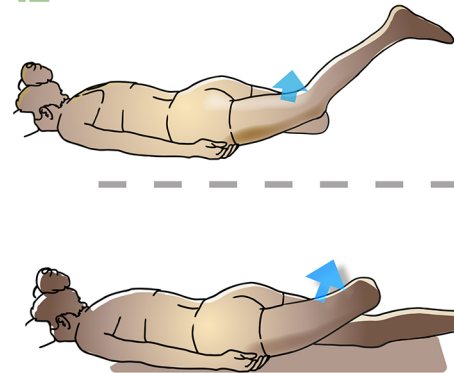
Is the pain where the limb used to be?

11



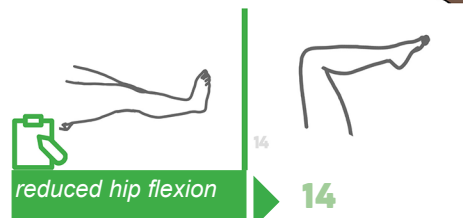
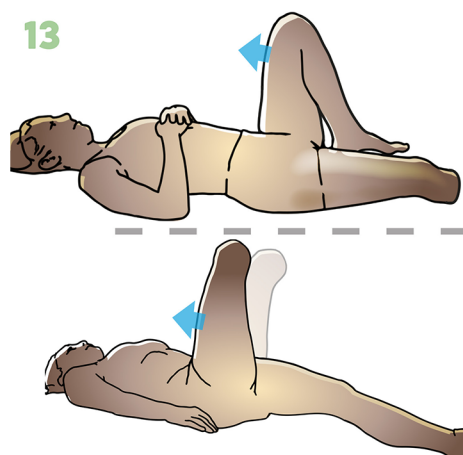
Does either hip have reduced extension?

12



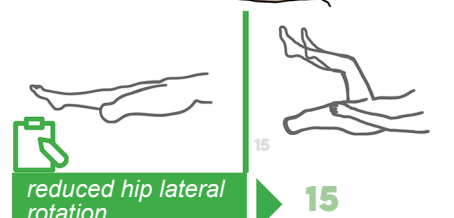
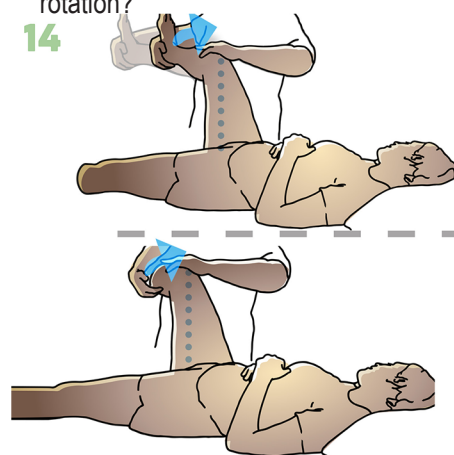
Does either hip have reduced flexion?

13



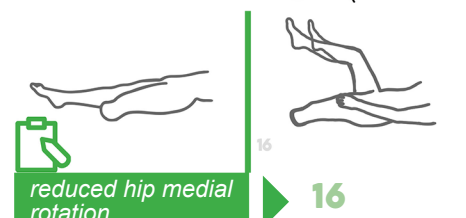
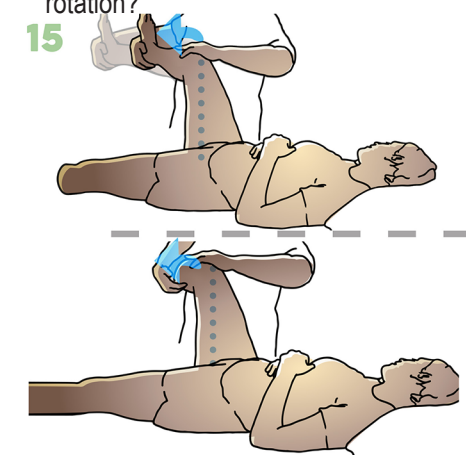
Does either hip have reduced lateral rotation?

14




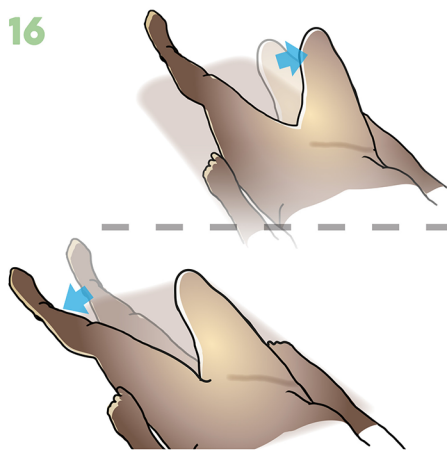
Does either hip have reduced medial rotation?

15



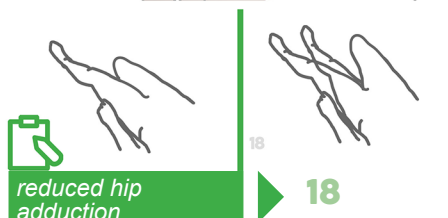
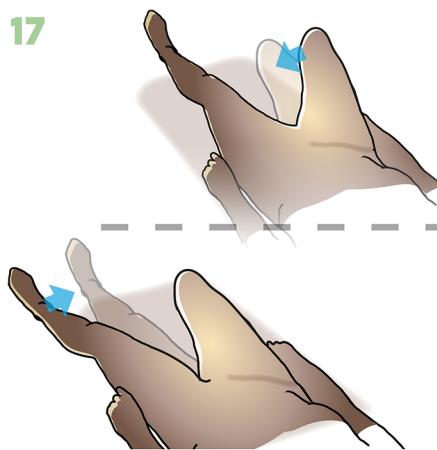
Does either hip have reduced abduction?

16



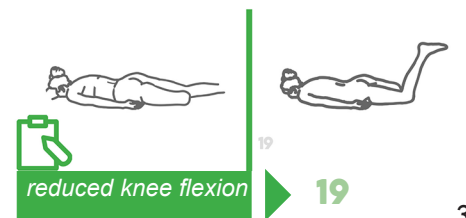
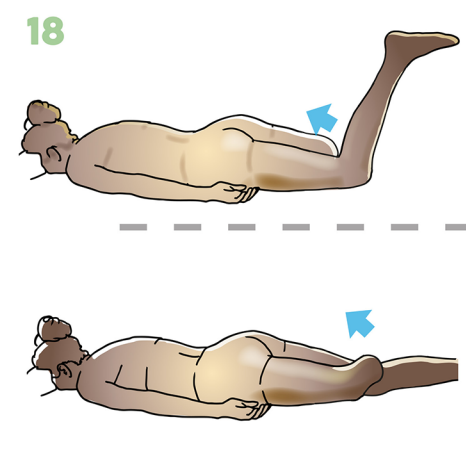
Does either hip have reduced adduction?

17



Does either knee have reduced flexion?

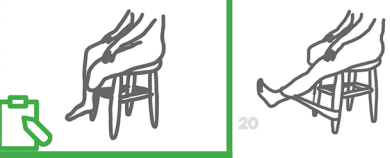
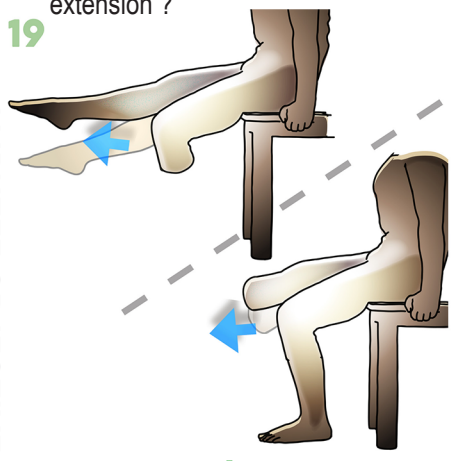
18



AMPUTEE OBJECTIVE ANALYSIS

Does either knee have reduced extension?

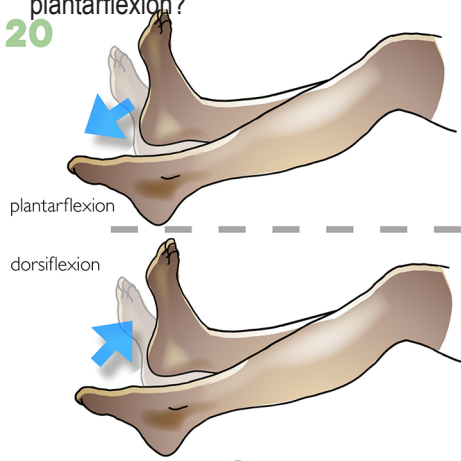
19



Reduced knee extension **20**

Is there reduced ankle dorsiflexion or plantarflexion?

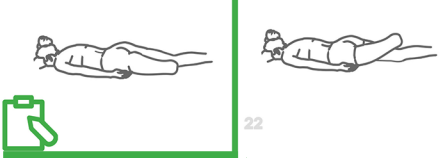
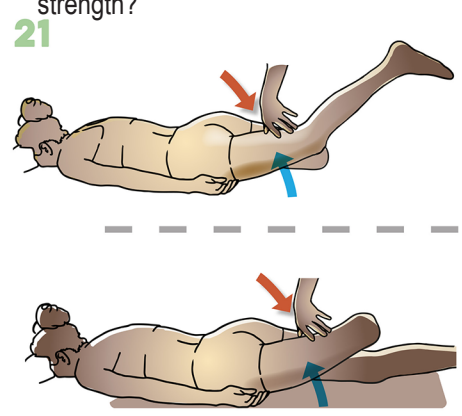
20



Reduced dorsiflexion or plantarflexion **21**

Does either hip have reduced extension strength?

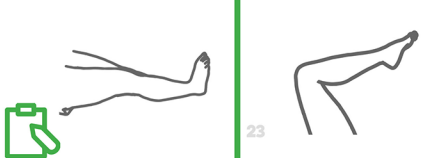
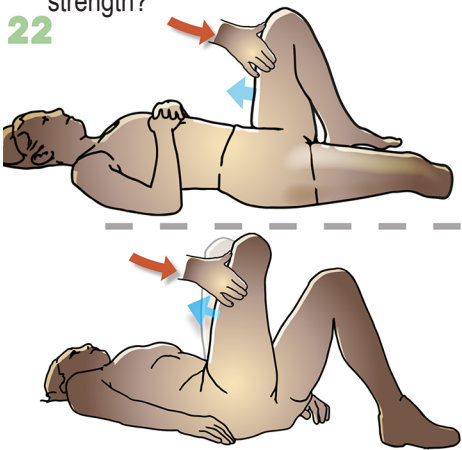
21



Reduced hip extension strength **22**

Does either hip have reduced flexion strength?

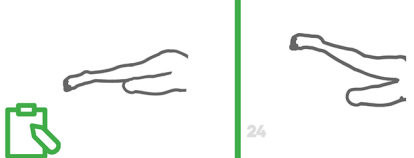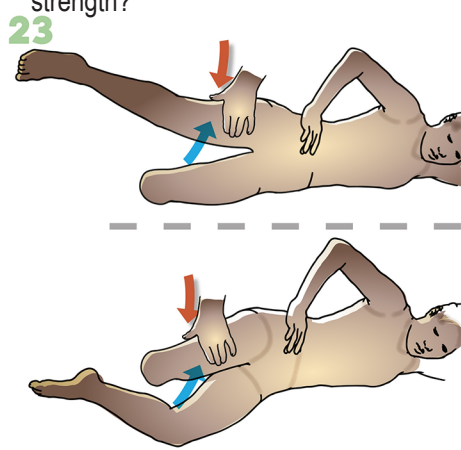
22



Reduced hip flexion strength **23**

Does either hip have reduced abduction strength?

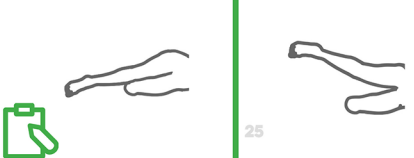
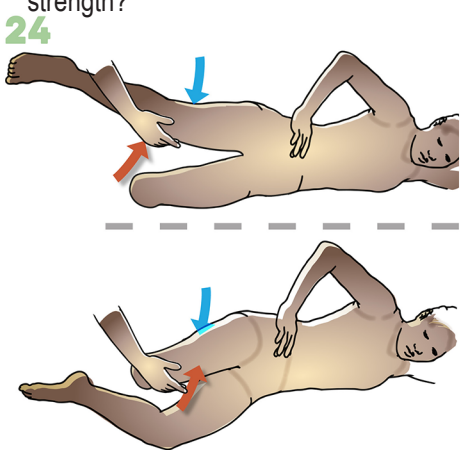
23



Reduced abduction strength **24**

Does either hip have reduced adduction strength?

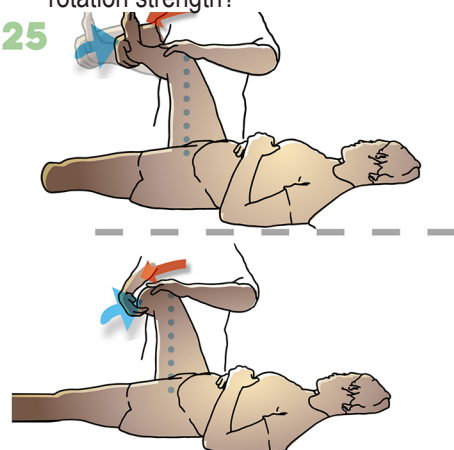
24



Reduced adduction strength **25**

Does either hip have reduced lateral rotation strength?

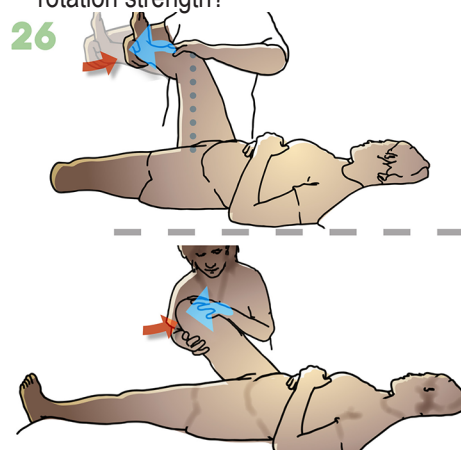
25



Reduced hip lateral rotation strength **26**

Does either hip have reduced medial rotation strength?

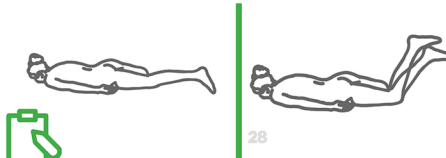
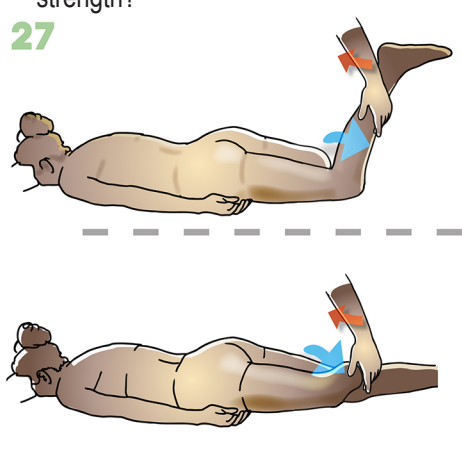
26



Reduced hip medial rotation strength **27**

Does either knee have reduced extension strength?

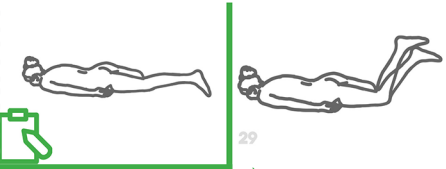
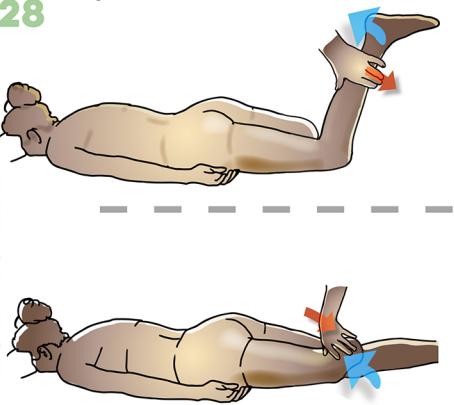
27



Reduced knee extension strength **28**

Does either knee have reduced flexion strength?

28

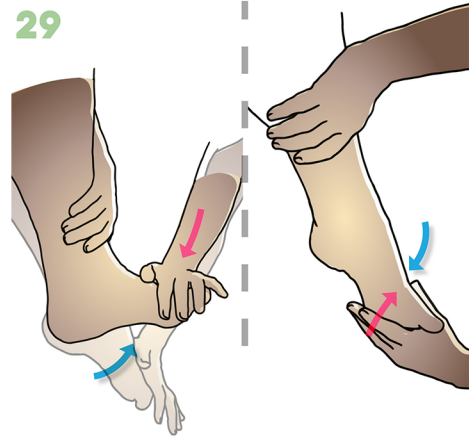


Reduced knee flexion strength

29

Does the ankle have reduced strength?

29

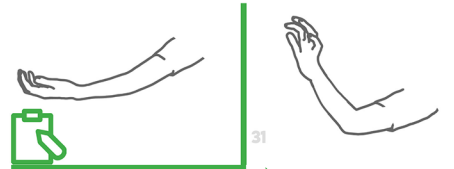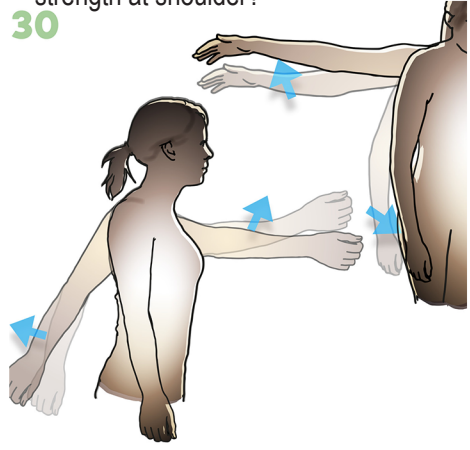


Reduced ankle strength

30

Does either arm have reduced ROM or strength at shoulder?

30

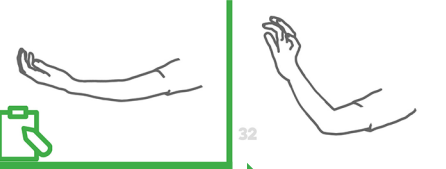
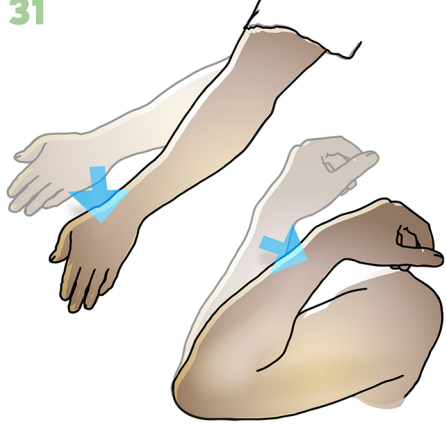


Reduced ROM or strength in shoulder

31

Does either arm have reduced ROM or strength at the elbow?

31

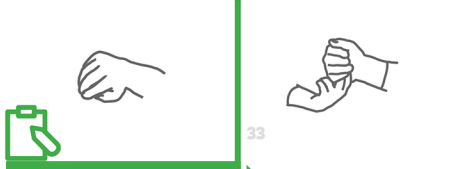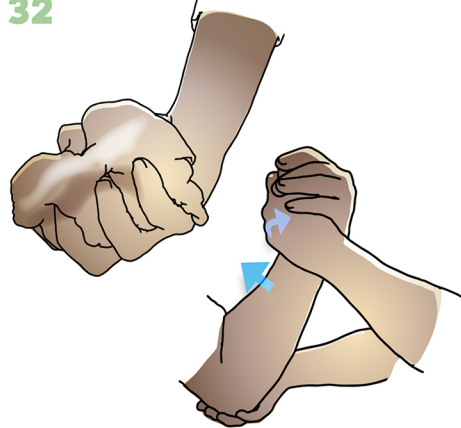


Reduced ROM or strength in elbow

32

Does either arm have reduced strength at the wrist or hand?

32

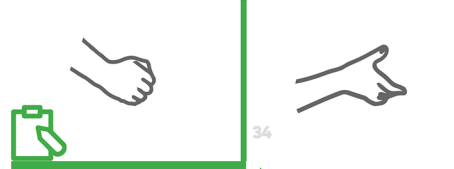
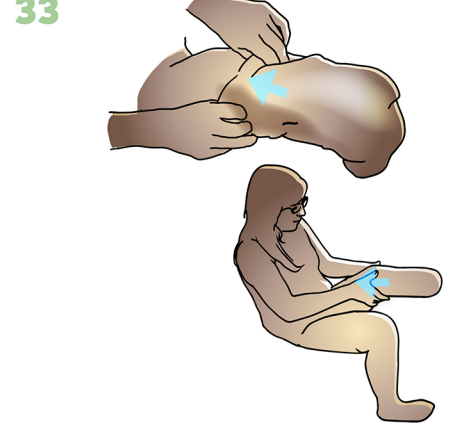


Reduced strength in hand

33

Does the patient have good hand dexterity?

33


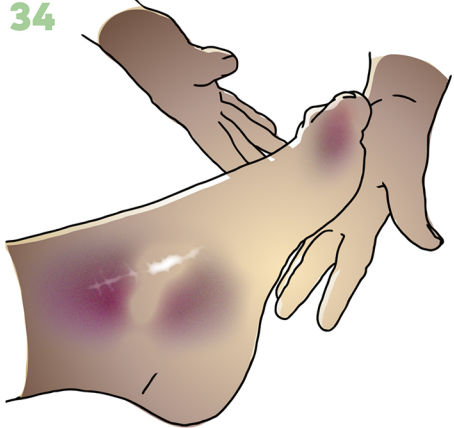


Make a note to inform prosthetist

34

Is the remaining foot healthy?

34

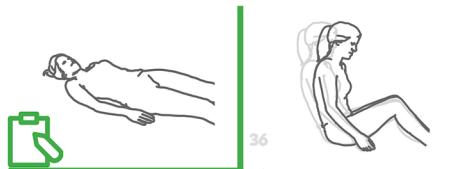



Unhealthy foot

35

Can the patient move safely around the bed?

35

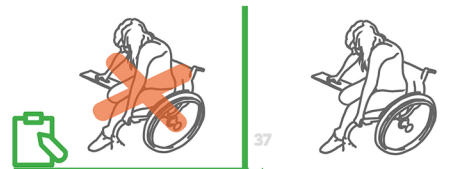
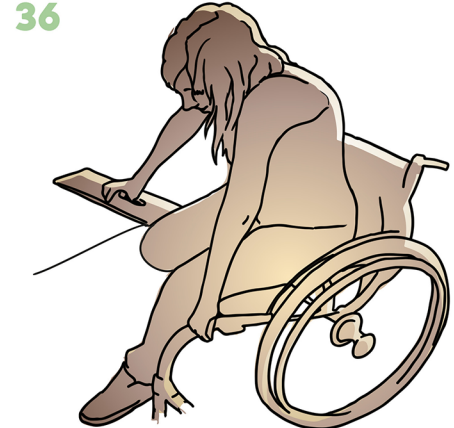


teach bed mobility

36

Can the patient transfer safely?

36

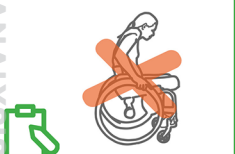

teach wheelchair transfers

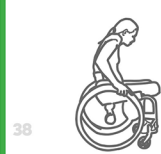37

Can the patient use the wheelchair safely?

37



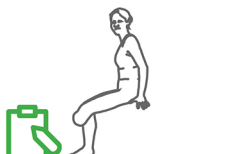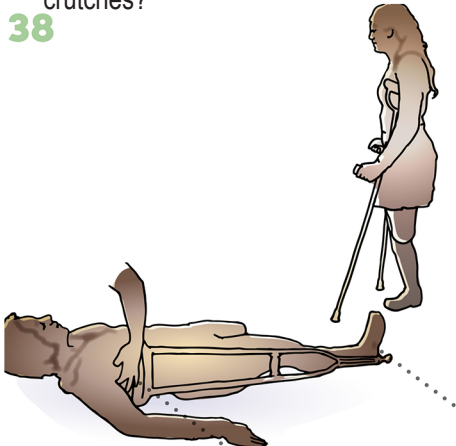teach safe use of wheelchair



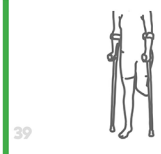
38

Has the patient been measured for crutches?

38



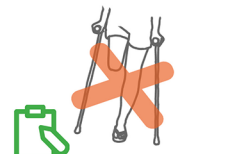measure for correct length of crutches



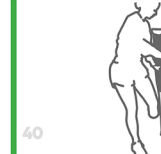39

Can the patient transfer safely with crutches?

39



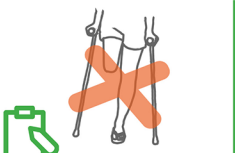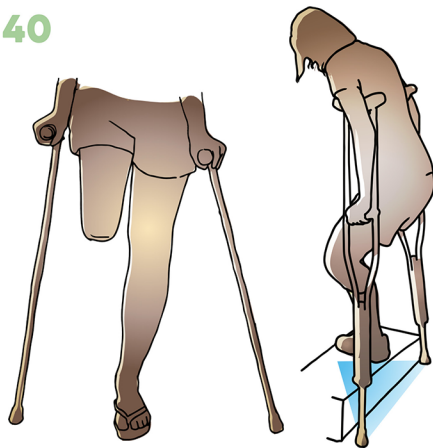
teach safe use of crutches for transfer



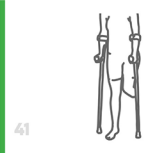40

Can the patient use crutches safely?

40



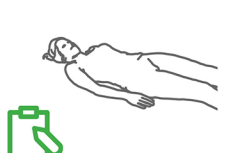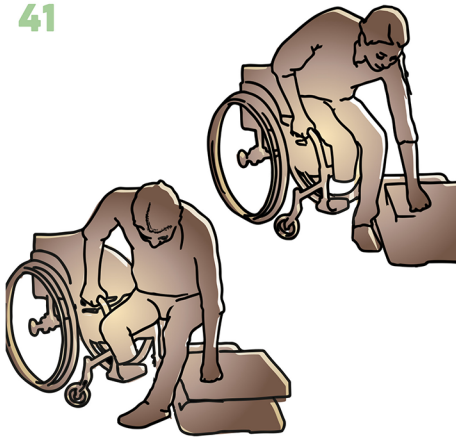teach use of crutches around location



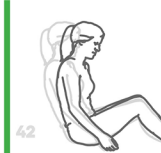41

Can the patient move from floor to chair/bed?

41



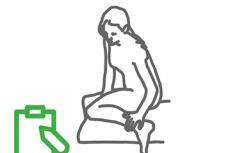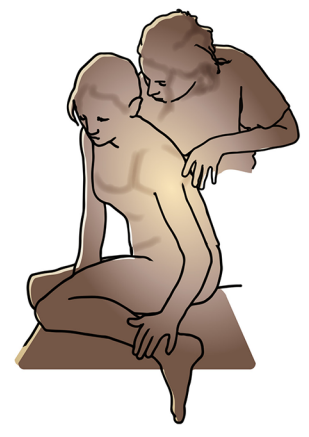teach floor/chair transfer



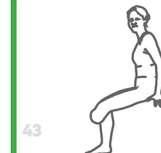
37

Is the patient free from anxiety and depression?

42



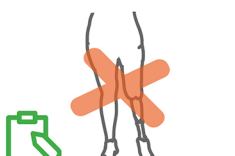
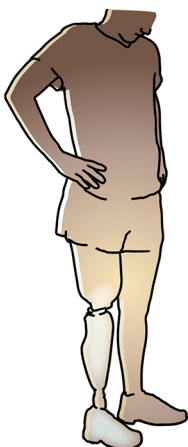refer to medic, monitor



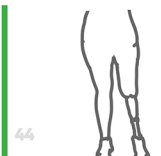
43

Based on this on-going assessment Is a prosthesis suitable for the patient?

43



END



44